



Workplace Safety and Insurance  
Appeals Tribunal

Tribunal d'appel de la sécurité professionnelle  
et de l'assurance contre les accidents du travail

---

# Dupuytren's Contracture

Discussion paper prepared for

The Workplace Safety and Insurance Appeals Tribunal

July 2002

Prepared by:

Dr. Lawrence N. Hurst MD FRCS(C)

Plastic, Reconstructive, Hand & Microsurgery

Dr. Lawrence N. Hurst graduated from the University of Toronto in 1965. He did post-graduate training in plastic surgery at the University of Toronto from 1966 to 1971 and was granted his fellowship in surgery in 1971. In 1972, he did a fellowship year at Stanford University Medical Centre in California and is American Board-Certified in Plastic Surgery. He joined the University of Western Ontario faculty in 1973 and held the rank of Chairman, Division of Plastic and Reconstructive Surgery. His clinical and research interests were in plastic, hand and micro surgery. He has published widely in these areas. He was Program Director, Residency Training Program of Plastic and Reconstructive Surgery from 1992 to 1997 at the University of Western Ontario and he currently holds the rank of Professor Emeritus.

WSIAT literature search reviewed by Dr. J. Duff in 2010, who is of the opinion that this paper still provides a balanced overview of the medical knowledge in this area.

This medical discussion paper will be useful to those seeking general information about the medical issue involved. It is intended to provide a broad and general overview of a medical topic that is frequently considered in Tribunal appeals.

Each medical discussion paper is written by a recognized expert in the field, who has been recommended by the Tribunal's medical counsellors. Each author is asked to present a balanced view of the current medical knowledge on the topic. Discussion papers are not peer reviewed. They are written to be understood by lay individuals.

Discussion papers do not necessarily represent the views of the Tribunal. A vice-chair or panel may consider and rely on the medical information provided in the discussion paper, but the Tribunal is not bound by an opinion expressed in a discussion paper in any particular case. Every Tribunal decision must be based on the facts of the particular appeal. Tribunal adjudicators recognize that it is always open to the parties to an appeal to rely on or to distinguish a medical discussion paper, and to challenge it with alternative evidence: see *Kamara v. Ontario (Workplace Safety and Insurance Appeals Tribunal)* [2009] O.J. No. 2080 (Ont Div Court).

## DUPUYTREN'S CONTRACTURE

Dupuytren's contracture is a fibroproliferative condition that primarily affects the palmar and digital fascia and can cause contractures of the metacarpal phalangeal and interphalangeal joints of the hand.

The palmar side of the hand can be thought of as a series of layers. Most superficially is the skin. Immediately under the skin is the palmar fascia which is a thin layer of fibrous tissue. Under this layer of fibrous tissue is a layer of tendons, nerves and blood vessels. The final and deepest layer is composed of muscles and bones.

The second layer down, the palmar fascia, starts to grow in Dupuytren's disease and initially forms a painful nodule in the palm [Figure 1].

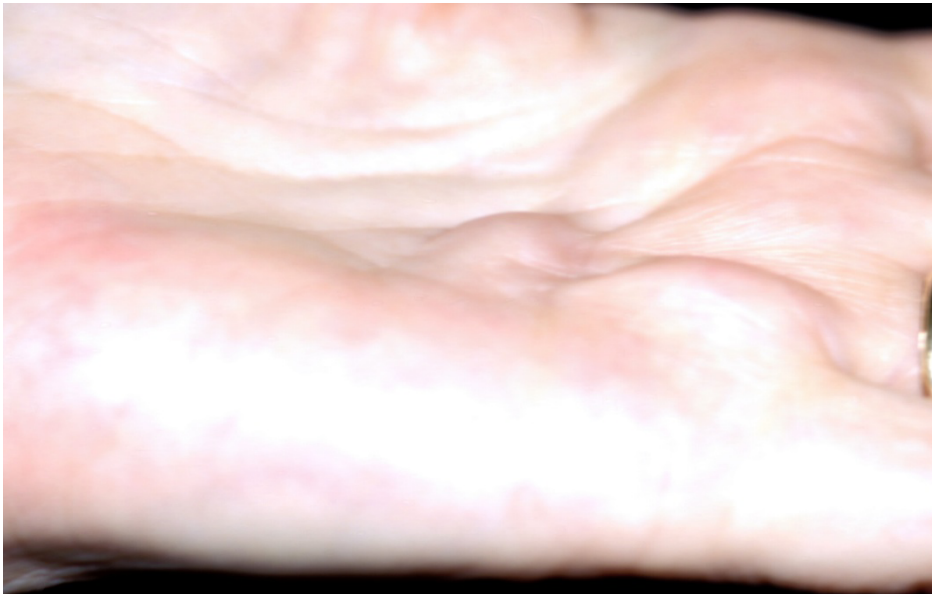

Figure 1: New Palmar nodule

The discomfort resolves spontaneously in several months. The fibrous tissue continues to grow and forms a pretendinous cord or hard band, detected on palpation, stretching from the palm to the base of a digit [Figure 2].

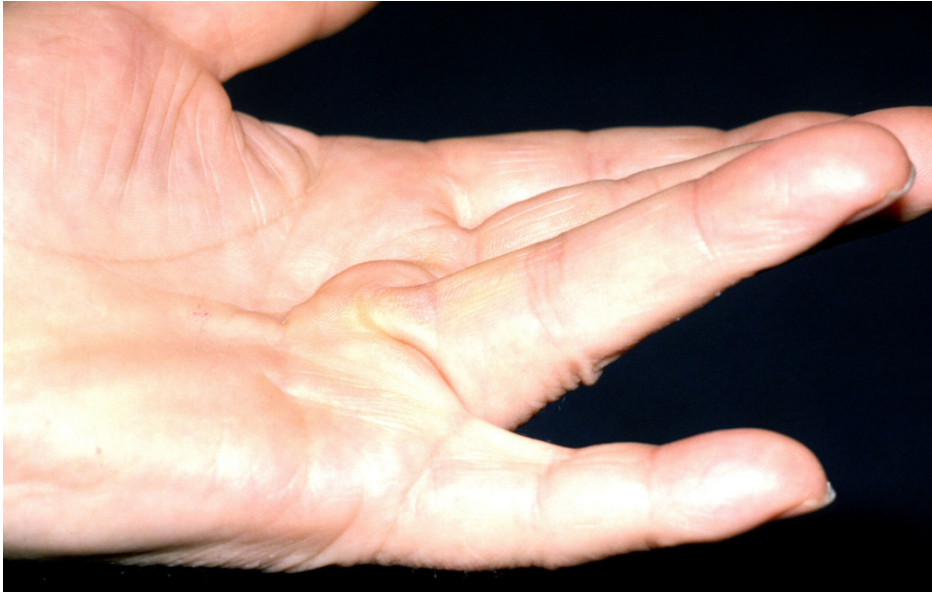

Figure 2: Pretendinous cord with flexion contracture of ring finger MP joint

The ring finger is most commonly affected first, followed by the small finger. The pretendinous cord can contract or shorten and cause a contracture of the metacarpal phalangeal joint (MCP). As the disease progresses, the contracture may involve the proximal interphalangeal joints and, rarely, the distal interphalangeal joints. The patient can always flex the fingers into his hand, but cannot fully extend them. The natatory cord can cause adduction of adjacent digits to the extent that they cannot be passively abducted. The inability to spread the fingers apart can cause skin maceration between the digits [Figure 3].

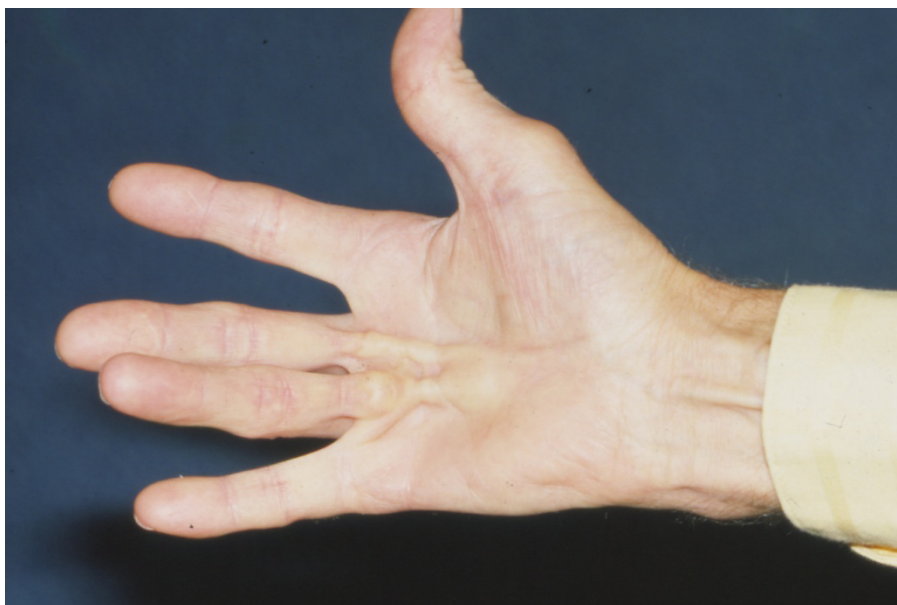

Figure 3: Natatory cords with inability to spread the ring and middle fingers

A severely contracted digit greatly interferes with both hand function and such routine activities as wearing gloves. The progress of the disease can be predicted to some extent and is determined by the patient, the presentation, and the associated conditions.

<b>Factors That Affect Control of Symptoms of Dupuytren's Contracture</b>	
<b>SUCCESSFULLY CONTROLLED</b>	<b>DIFFICULT TO CONTROL</b>
No family history	Strong family history
Minimal involvement	SBilateral involvement
Late presentation	Early presentation
No intercurrent disease	Intercurrent disease (e.g. epilepsy, diabetes, alcoholism, infection with HIV)
No associated conditions	Associated conditions (e.g. knuckle pads, plantar fibromatosis, Peyronie's disease)
Patient compliant with rehabilitation program	Patient not compliant with rehabilitation program

The fibroblast in the fascia structurally changes to the myofibroblast described by Majno (1). This cell has the ability to actively contract and is responsible for the contractures seen in Dupuytren's contracture.

## Incidence

The incidence of Dupuytren's contracture varies widely among races and is high among the descendants of the Celtic race which originally inhabited Northern Europe and the British Isles. McFarlane (2) reported a survey in which 82 percent of the patients with Dupuytren's disease were from Northern European families. There was a higher incidence among males with a male to female ratio of 82:16 which was consistent in all countries. Bower (3) reported that the incidence of Dupuytren's disease among individuals with human immunodeficiency virus (HIV) exceeds that of the general population.

Dupuytren's disease is a genetic disease and is inherited by means of an autosomal-dominant gene with variable penetrance (4). The expression of the gene is less complete in females, which accounts for the lower incidence and later onset among the female population (5). The onset of Dupuytren's disease usually occurs in the fifth decade in males and the sixth decade in females, and the disease is gradually progressive.

Trauma is often cited as a causative agent, but McFarlane (6) believes that evidence from epidemiological studies is insufficient to support this conclusion in most cases. However, a causal relationship may be considered in young patients who develop Dupuytren's contracture within two years of sustaining a single injury.

In 1996 Liss and Stalk (7) reported that there is good support for an association between vibration exposure and Dupuytren's disease, but weaker evidence for an association with manual work. McFarlane thoroughly reviewed all the papers that have related both vibration exposure and manual work to Dupuytren's disease and concluded that vibration injury has only a possible relation and that a relation to manual work is unproven. This information is documented in the report "*Dupuytren's Disease: The Relation to Manual Work, Vibration Exposure and a Single Injury to the Hand*". This was an update requested by the Workmen's Compensation Appeals Tribunal submitted by Dr. Robert M. McFarlane, December 1996.

Microtrauma is a term coined by Dr. Skoog in 1948 to draw attention to microruptures in the palmar fascia. He regarded them as a result of multiple injuries contributed to by hard work. Larson in 1960 found the same histological pattern in experimental ruptures of the palmar fascia in apes as in Dupuytren's disease in man, but none of the apes developed a finger contracture. Consequently, the study was unable to show that microtrauma has any relationship to Dupuytren's contracture. Dupuytren's contracture and carpal tunnel syndrome can occur in the same patient; however, no cause and effect relationship has ever been shown between the two diseases.

### Associated Conditions:

Dupuytren's contracture is associated with other malformations of fibrous tissue proliferation, including knuckle pads [Figure 4].

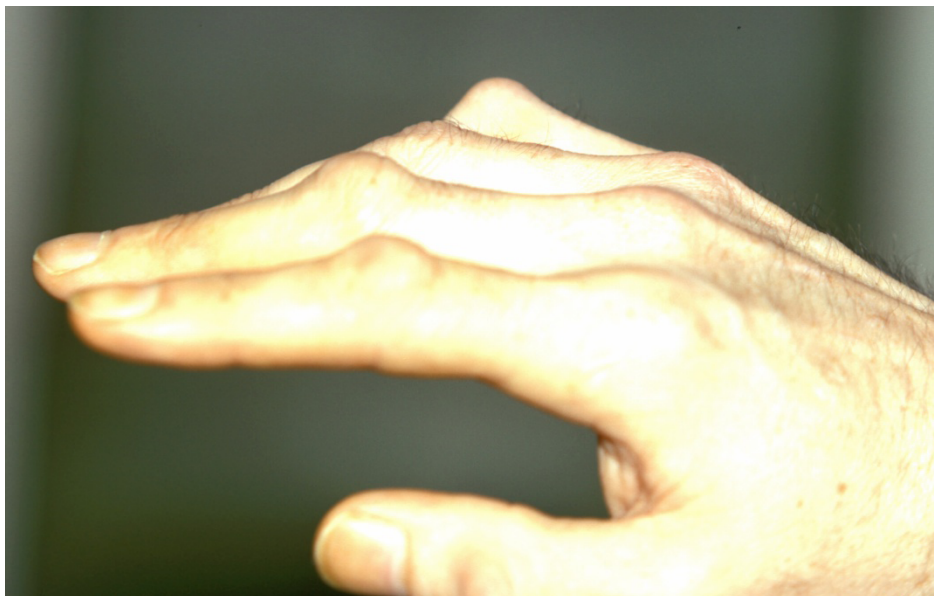

Figure 4: Knuckle pads over the dorsal PIP joints

The knuckle pads appear as nodular thickenings over the dorsum of the PIP joints. They can be tender, but do not cause contractures and sometimes regress spontaneously. The deposition of fibrous plaques on the dorsum of the penis in Peyronie's disease causes a painful penile contracture in response to erection. The plantar fascia proliferates in plantar fibromatosis in a fashion similar to that of the palmar fascia in Dupuytren's contracture. Flexion contractures rarely occur in the toes (8), but nodules may appear in the plantar fascia, usually in the instep [Figure 5].

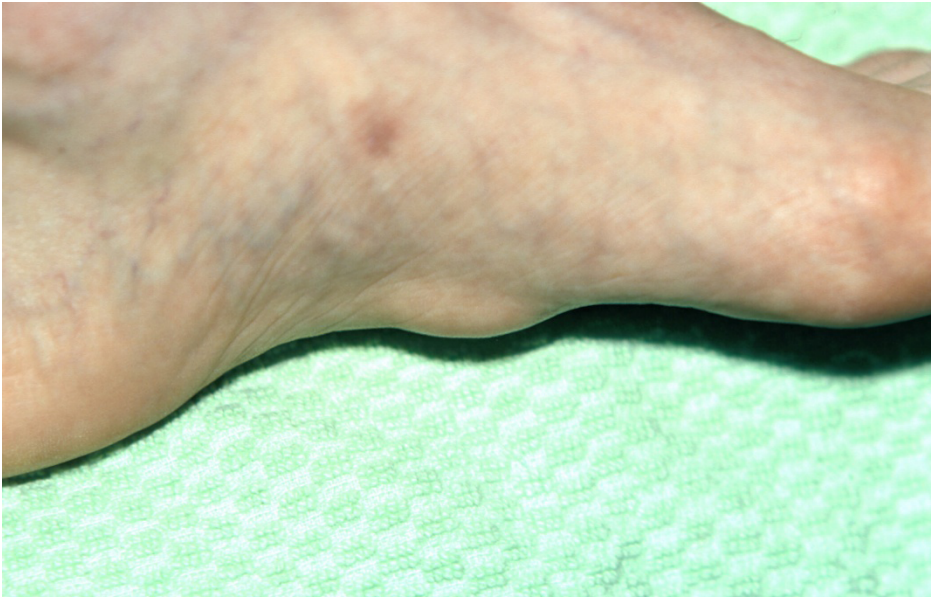


Figure 5: Plantar nodule

Houston (9) described the clinical features of patients with particularly aggressive Dupuytren's contracture, which include a positive family history, the appearance of disease before the age of 40, knuckle pads, plantar fibromatosis, and severe bilateral involvement. Such patients have a strong Dupuytren's diathesis and therefore should be identified because of a strong tendency for the disease to progress and recur after treatment.



### **Associated Diseases:**

A greater incidence of Dupuytren's contracture occurs among individuals with epilepsy (10). In these patients, the disease presents at an earlier age, has a normal distribution on the ulnar side of the hand and is bilateral and aggressive. The incidence increases with the age of the patient and the duration of the epilepsy. Individuals with idiopathic and traumatic epilepsy are affected equally; consequently, the increased incidence among this population is thought to be caused by the long-term effects of barbiturate therapy (11).

Dupuytren's contracture is common among individuals with diabetes, and the incidence increases with the age of the patient and the duration of the diabetes (12, 13). The distribution of the disease is more radial in the hand, with nodules typically appearing at the base of the middle and ring fingers. Involvement is mild and mainly in the palm with few contractures of the fingers. Surgery may not be required. The connection between diabetes and Dupuytren's contracture is most likely related to the diabetic microangiopathy, which causes disturbances in the structural macromolecules in the extracellular matrix and results in the inappropriate deposition of connective tissue (12).

The association of Dupuytren's contracture with alcoholism, with or without cirrhosis, has been studied by many authors (14, 15, 16), and reports show an increased incidence of Dupuytren's contracture among alcoholic patients. The distribution of the disease in such patients mainly involves a thickening in the palmar aponeurosis without significant contractures; however, the disease can be very aggressive, leading to severe joint contractures in some cases. The association may be related to the amount of alcohol ingested and its effects on the microcirculation. Dupuytren's contracture has been strongly associated with both smoking and HIV infection (17).

### **Non-surgical treatments:**

Non-surgical treatments, to date, have not been successful. Standard splints cannot prevent or reverse contractures. Ultrasound, laser therapy, and radiation have been ineffective, and vitamin E and enzymatic fasciotomy have also not been proven to be of long-term value unless combined with surgical treatment (18, 19, 11). However, Ketcham (20) has produced beneficial results by the injection of steroids into early painful palmar nodules to reduce symptoms. Skeletal traction has also been effective in reversing joint contractures in the preoperative patient (21, 22). Dr. Lawrence C. Hurst, an orthopedic surgeon from Stoneybrook, New York, is presently engaged in a multi-center trial of collagenolytic agents. His preliminary studies are very encouraging for the non-surgical release of joint contractures.

Current research is focused at the cellular level to investigate such parameters as macrophage growth factor, oxygen free radicals, and the possible role of hypoxia and cytokines. Perhaps with a clear understanding of cellular biology, we may improve control of the cellular activity. Currently, we are in the "stone age" with regard to the treatment of Dupuytren's contracture. Rather than carve out diseased tissue, genetic engineering should allow us to control the development of the disease. Until this type of control is possible, however, surgery is our most effective treatment.

### **Indications for Surgery:**

The development of a palmar nodule or a pretendinous cord in the early stages of Dupuytren's contracture is not necessarily an indication for surgery. However, some manual workers, such as carpenters and mechanics, have difficulty because the palmar nodule can be painful and can interfere with their hand function and occupation. If steroid injection of the nodule is ineffective in reducing symptoms, a limited excision of the painful nodule allow can allow the patient to continue working. The nodules become asymptomatic with time, but some patients require symptomatic relief. Houston's (23) "table top test" determines when a patient has reached the stage of being unable to place the hand flat on a surface because of MCP joint contractures. Early MCP joint contractures may be followed, but a MCP joint contracture of 30 degrees or more should be released (24). Even severe MCP joint contractures can usually be completely corrected; however, contractures of the PIP joints are not as easily corrected. A PIP joint contracture of 30 degrees or more is an indication for surgery (25) as is a severe adduction contracture which can cause skin breakdown because of the patient's inability to separate the digits. Figure 6 and 7 show a preoperative patient with a flexion contracture of the small and ring finger MP joints and the small, ring and middle finger PIP joints. Figure 8 shows a preoperative patient still able to make a full fist.



Figure 6: Preoperative patient with a flexion contracture of the small and ring finger MP joints and the small, ring and middle finger PIP joints

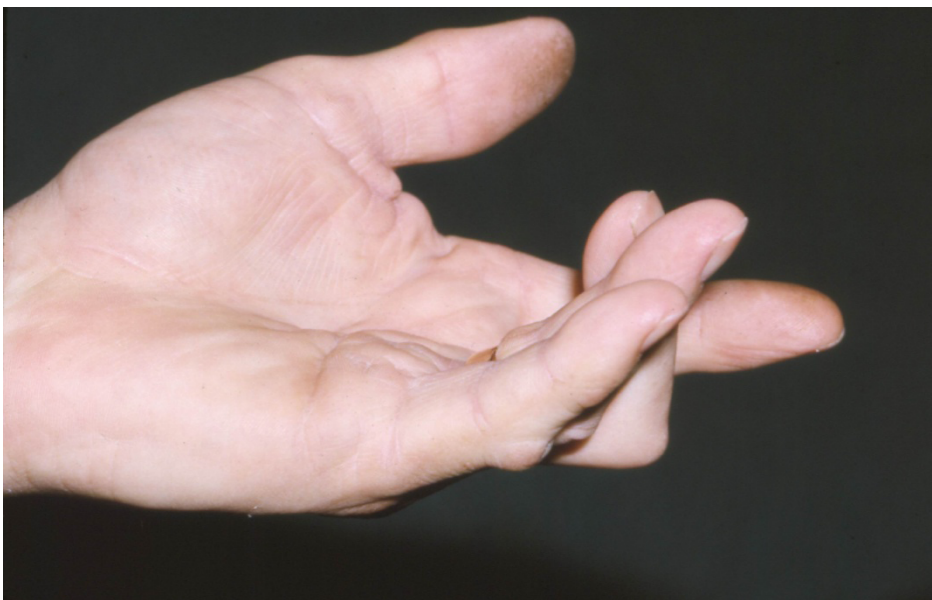

Figure 7: Preoperative patient with a flexion contracture of the small and ring finger MP joints and the small, ring and middle finger PIP joints

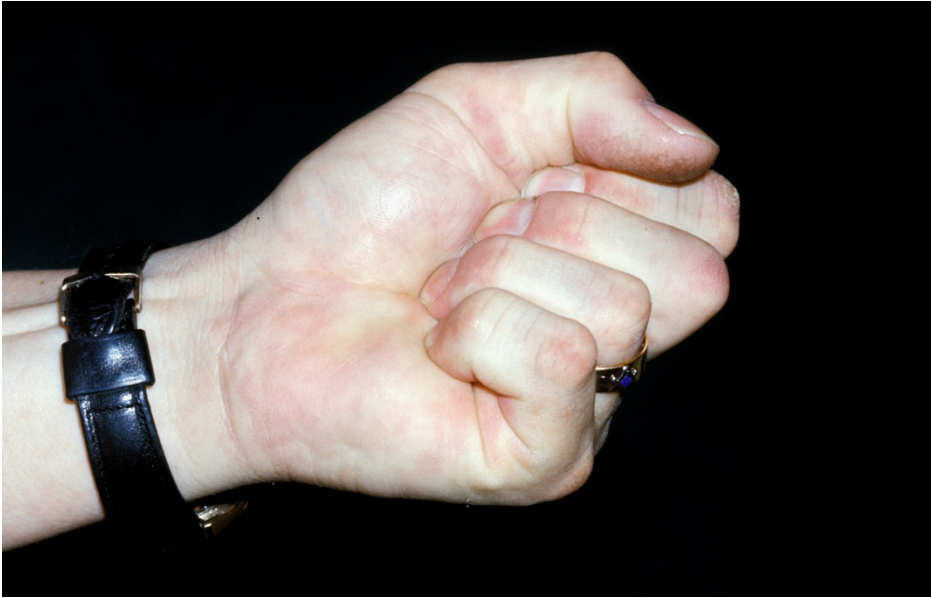

Figure 8: Preoperative patient still able to make a full fist

### Treatments

It is important to educate patients regarding the surgical treatment and rehabilitation of Dupuytren's contracture so that their expectations are realistic. The goal is to correct both the contracture in the fingers and the cords in the palm. Surgery cannot cure the disease itself. As previously indicated, correction of the MCP joint contractures is usually successful, but PIP joint contractures are much more difficult to release; cannot always be fully corrected; and have a higher recurrence rate, particularly in the small finger (25).

### Regional Fasciectomy

Regional fasciectomy is the most common fasciectomy performed for the surgical treatment of Dupuytren's contracture. This procedure completely excises the diseased fascia in the palm and digits, but spares the normal-appearing fascia. This operation can be performed under block or general anesthesia with tourniquet control and loop magnification. The most commonly used incision is the zigzag or Bruner incision (26), but the mid-axial, straight-line, longitudinal incision may be used and closed with multiple z-plasties to break the straight line. Figures 9 and 10 show a postoperative patient following a palmar fasciectomy to release his left ring and small finger flexion contractures. Figure 11 shows the same postoperative patient making a full fist.

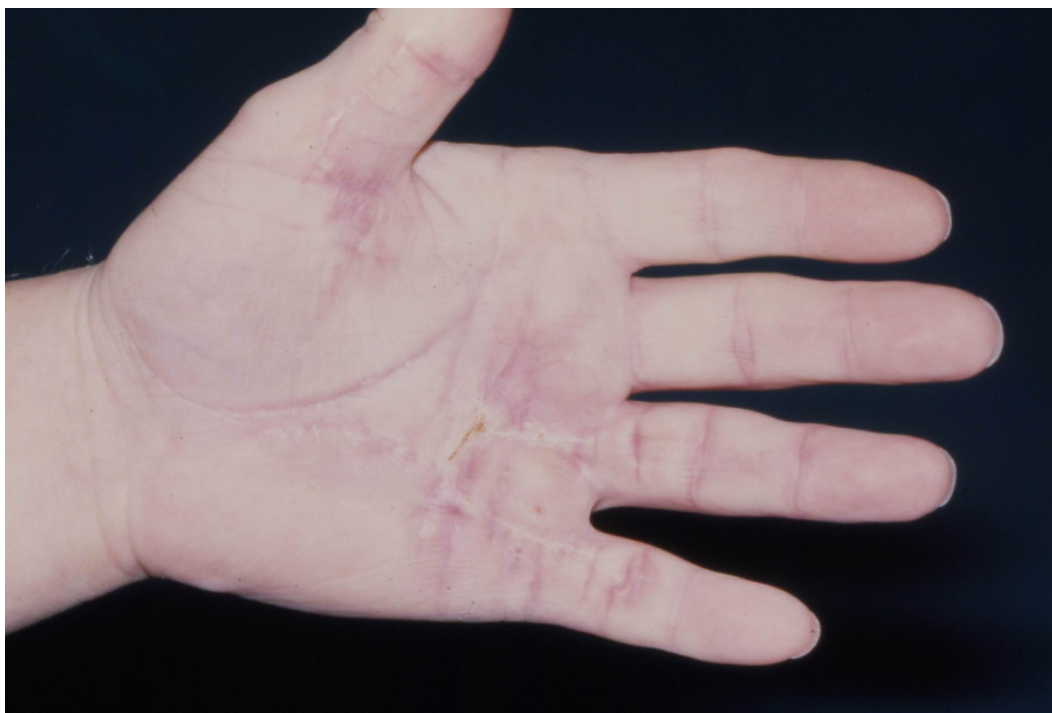

Figure 9: Postoperative patient following a palmar fasciectomy to release his left ring and small finger flexion contractures

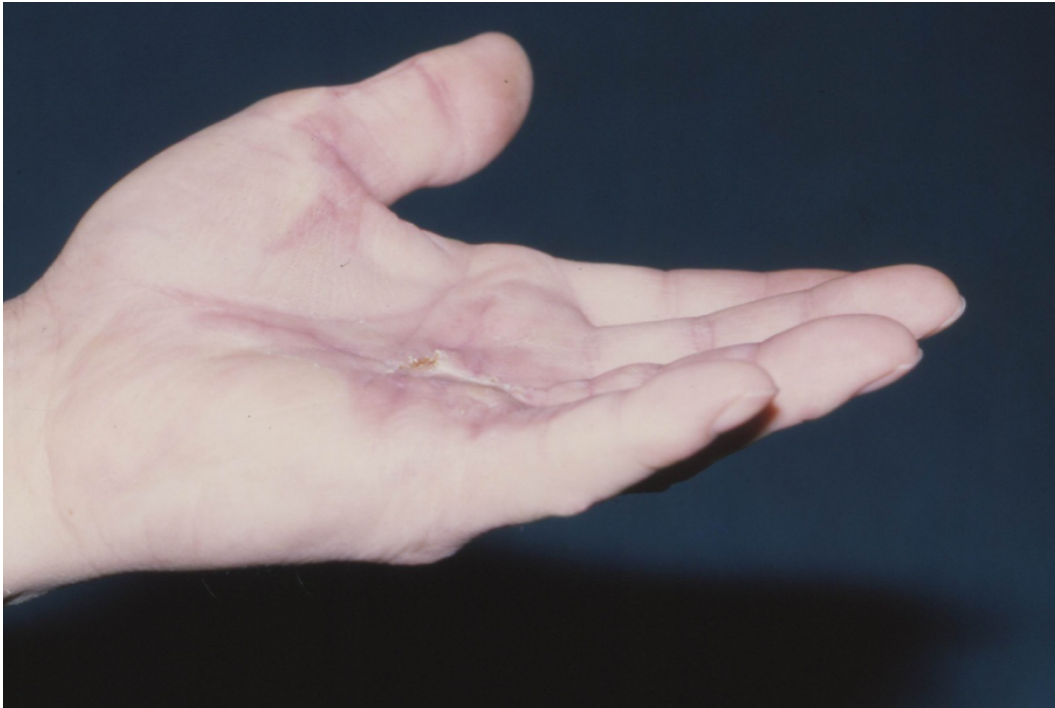

Figure 10: Postoperative patient following a palmar fasciectomy to release his left ring and small finger flexion contractures

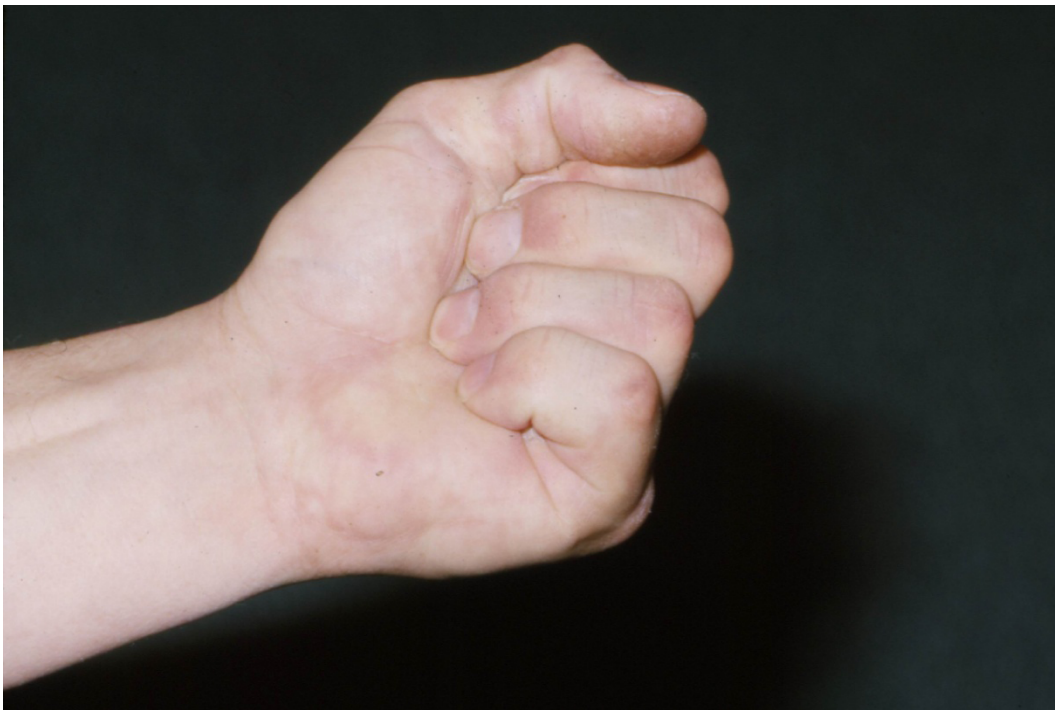

Figure 11: Same postoperative patient making a full fist

### **Radical Fasciectomy**

The radical fasciectomy is reserved for patients with extensive disease such as those with Dupuytren's diathesis as described by Houston (9). Both the disease and the normal appearing fascia are excised from the palm and affected fingers. This more extensive resection is accompanied by increased postoperative morbidity because of swelling and stiffness.

### **Dermatofasciectomy**

Dermatofasciectomy was described by Houston (27) for patients with an aggressive diathesis and skin involvement. Both the diseased fascia and the overlying skin are excised. The tissue defect is replaced by a full thickness skin graft. According to Houston, the skin graft decreases the recurrence rate (28).

### **Open Palm Technique**

The open palm technique described by McCash (28) involves transverse incisions in both the palm and the fingers that are not closed but rather left open to spontaneously re-epithelialize, usually in 4 to 6 weeks. This technique avoids hematoma formation, is painless, and allows immediate mobilization of the fingers. In this procedure, though, daily dressings are required for an extended period.

### **Skeletal Traction**

Skeletal traction (22) has been successfully used to straighten contractures. Rapid recurrence takes place after the traction is removed unless it is followed by surgery. The technique is useful for facilitating fasciectomy in severely contracted digits.

### **Secondary Procedures**

Surgical resection of the involved fascia cannot cure the disease, but it attempts to control its symptoms. Both recurrence and extension of the disease occur, and Gonzales (30) found that no patient followed longer than 10 years after the initial procedure was free of disease. Secondary disease presents a far more difficult problem than primary disease. Normal tissue planes are lost after the initial operation, and incisions are generally dictated by the previous scars. Elevation of the skin flaps over the newly-formed diseased fascia necessitates an exacting technique. The neurovascular

bundles are frequently very superficial in some areas. They require identification in virgin tissue first, and subsequent meticulous dissection into the diseased fascia. The patency of both the radial and ulnar vascular bundle should be checked because one or the other may have been previously damaged. Unfortunately, normal anatomy does not exist.

### **Amputations**

Amputations, as secondary procedures (particularly of the little finger), may result in many problems including lack of extension, neuroma formation, and phantom limb symptoms. Jensen (31) advises alternatives to amputation; however, in specially selected patients who have both aggressive recurrent disease and severe contractures of the PIP joint of the small finger, I have found amputation to be very effective. The normal dorsal skin of the middle phalanx is used to cover the defect from the excision of the skin and diseased fascia over the palmar aspect of the proximal phalanx. This technique completely frees up the MCP joint. Patient satisfaction has been very high when this technique has been used. Moreover, the full width of the palm is retained which helps stabilize tools such as hammers and wrenches during power grip.

### **Postoperative Management**

Most patients undergo surgery as outpatients and return to the clinic the next day. The preoperative educational program is most beneficial at this time because the patient expects to conform to the protocol that was carefully explained at the initial consultation. The dressings, splint, and drains are removed, and the hand is fully checked for early problems such as undue swelling, hematoma formation, or wound complications. It is most unusual to encounter any of these potential difficulties at this stage. A light dressing is applied, and the patient's care is immediately referred to the hand therapist.

The therapist already has a preoperative, well-documented baseline of the patient. Additional information from the surgical procedure such as the amount of correction gained at surgery, the degree of any remaining contractures, the extent of the wound, and the reaction of the patient and the tissues to surgery is recorded. The splinting requirements of the patient are assessed on an individual basis. Isolated palmar involvement without contracture does not require splinting, and a range of motion program with light hand use is initiated on the first postoperative day.

The hand of the patient with early disease may be easily positioned in extension with a volar-based hand splint. A forearm-based splint is used when there is more extensive involvement.



Therapy programs are tailored to each case. The patient is instructed to remove the splint for dressing changes with skin care as directed and to perform (4 to 6 times per day) specific, gentle, and active range of motion exercises including composite flexion and extension. The patient's progress is carefully monitored, and the program can usually be upgraded at the end of the first week. The sutures are removed two weeks after surgery, and the patient's rehabilitation program progresses and is monitored by the therapist.

### Outcomes

### Complications

Complications occur frequently. A large multi-center survey reported a complication rate of 19 percent (24) which include hematoma formation, skin loss, infection, nerve or arterial division, loss of flexion and reflex sympathetic dystrophy. First, the incidence of hematoma can be decreased by ensuring that the patient discontinues aspirin, anticoagulants, non-steroidal anti-inflammatory agents, vitamin E, vitamin B12, and any other agent known to affect coagulation before surgery. These agents may be restarted on the first day after surgery.

Flap necrosis can be caused by a neglected hematoma, devascularization of the flaps, or a button holing of the flaps while reflecting the skin at the start of surgery. Dissection is made more difficult by palmar pits, severely contracted joints, or recurrent disease. Magnification loops are invaluable in these situations because they allow the surgeon to remove all diseased tissue while preserving normal structures. Infection is rare, but can accompany a hematoma. The hematoma is treated by draining, culturing the wound, and using appropriate systemic antibiotics with repeated local dressing changes. Swelling from an infection is accompanied by joint stiffness: thus, appropriate, guarded therapy should be started early.

Nerve and vessel injuries can occur in the most expert hands, particularly during secondary procedures. Such injuries must be immediately recognized to avoid resection of nerve and vessel, which may compound the problem. A nerve injury should be repaired before closure by microsurgical technique. Even after uncomplicated fasciectomy, when the nerve is in continuity, the sensation to the digit is often decreased. In a multi-center survey, decreased flexion was reported to occur at a rate of 6 percent (25). Reflex sympathetic dystrophy has been reported in 4 percent of male patients and 8 percent of female patients (30). Dystrophy should be differentiated from the flare reaction that reflects soft tissue response to the trauma of surgery.

Complaints of swelling, stiffness, and burning pain, sometimes occurring several weeks after surgery, should cause the surgeon to suspect reflex sympathetic dystrophy. Active therapy in conjunction with the use of non-steroidal anti-inflammatory agents, elevation, and sympathetic blocks are useful and help to alleviate these symptoms.

### **Clinical Outcomes**

Rivers (32) found a statistically significant difference in the mean improvement in proximal interphalangeal (PIP) joint extension in patients who complied with the postoperative extension splinting program, compared with patients who did not comply. The metacarpal phalangeal joint can usually be significantly corrected, but the interphalangeal joints are rarely completely corrected, particularly in the small finger. The small finger proximal interphalangeal joint is frequently affected by more severe disease (24).

Healey (33) reported the development of a "statistically valid outcome measure for assessing symptom and function scores and patient satisfaction after surgical correction of Dupuytren's disease" using the SF-36 questionnaire. Patient satisfaction strongly correlated with improved postoperative function scores, improved postoperative symptom scores, and surgery on the dominant hand.

### **Summary**

Management of the patient with Dupuytren's contracture encompasses the whole spectrum of care of the surgical patient. Dupuytren's contracture is not life-threatening, but also is not curable. Education is essential to ensure that the patient understands the natural history of the disease and the limitations of current treatment methods. At present, though, for a patient with debilitating Dupuytren's contracture, a surgical procedure immediately followed by a rehabilitation program can produce an excellent improvement in hand function.

Table of Figures

Figure No.	Title
Figure 1	New Palmar nodule
Figure 2	Pretendinous cord with flexion contracture of ring finger MP joint
Figure 3	Natatory cords with inability to spread the ring and middle fingers
Figure 4	Knuckle pads over the dorsal PIP joints
Figure 5	Plantar nodule
Figure 6 & 7	Preoperative patient with a flexion contracture of the small and ring finger MP joints and the small, ring and middle finger PIP joints
Figure 8	Preoperative patient still able to make a full fist
Figure 9 & 10	Postoperative patient following a palmar fasciectomy to release his left ring and small finger flexion contractures
Figure 11	Same postoperative patient making a full fist

References

1. Majno G, Gabbiani G, Hirschel BJ, et al. Contraction of granulation tissue in vitro. *Science* 173:548, 1971.
2. McFarlane RM. Unpublished data from the Dupuytren's disease committee of the International Federation of Societies for Surgery of the Hand, 1985.
3. Bower M, Nelson M, Gazzard BG. Dupuytren's contracture in patients affected with HIV. *BMJ* 300:164, 1990.
4. Ling RSM. The genetic factors in Dupuytren's disease. *J Bone Joint Surg* 45B:709, 1963.
5. Matthews P. Familial Dupuytren's contracture with predominantly female expression. *Br J Plast Surg* 32:120, 1979.
6. McFarlane RM. Dupuytren's disease: relation to work and injury. *J Hand Surg (Am)* 16:775, 1991.

7. Liss GM, Stock SR. Can Dupuytren's contracture be work related? Review of the evidence. *Am J Indus Med* 29:521, 1996.
8. Classen DJ, Hurst LN. Plantar fibromatosis: a case report of bilateral flexion contractures and review of the literature. *Ann Pl Surg* 28:475, 1992.
9. Hueston JT. State of the art: the management of recurrent Dupuytren's disease. *Eur Med Bibliography* 1:7, 1991.
10. Critchley EMR, Vakil SDF, Hayward HW, et al. Dupuytren's disease in epilepsy: result of prolonged administration of anticonvulsants. *J Neural Neurosurg Psychiatry* 39:498-504, 1976.
11. McFarlane RM. The current status of Dupuytren's disease. *J Hand Ther* 8:181, 1995.
12. Crisp AJ, Heathcote JG. Connective tissue abnormalities in diabetes mellitus. *J R Coll Physicians Lond* 18:132, 1984.
13. Noble J, Heathcote JG, Cohen H. Diabetes mellitus in the etiology of Dupuytren's disease. *J Bone Joint Surg* 66B:322, 1984.
14. Bradlow R, Mowat AG. Dupuytren's contracture and alcohol. *Ann Rheum Dis* 45:304-307, 1986.
15. Sabiston DW. Cataracts, Dupuytren's contracture, and alcohol addiction. *Am J Ophthalmol* 75:1005, 1973.
16. Su CK, Patek AJ Jr. Dupuytren's contracture: its association with alcoholism and cirrhosis. *Arch Intern Med* 126:278, 1970.
17. Murrell GA. An insight into Dupuytren's contracture. *Ann Roy Coll Surgeons England* 74:156, 1992.
18. Berger A, Pelbruck A, Brenner P, et al. Dupuytren's disease. New York, 1994, Springer-Verlag.
19. McCarthy DM. The long term results of enzymatic fasciotomy. *J Hand Surg (Br)* 17:356, 1992.
20. Ketchum LD. The use of the full thickness skin graft in Dupuytren's contracture. *Hand Clin* 7:731, 1991.
21. Hueston JT. Regression of Dupuytren's contracture. *J Hand Surg (Br)* 17:453, 1992.

22. Messina A, Messina J. The continuous elongation treatment by the TEC device for severe Dupuytren's contracture of the fingers. *Plast Reconstr Surg* 92:84, 1993.
23. Hueston JT. Dupuytren's contracture: selection for surgery. *Br J Hosp Med* 13:361, 1974.
24. McFarlane RM. Dupuytren's disease. In McCarthy JG (editor): *Plastic Surgery*. Philadelphia, 1990, WB Saunders.
25. McFarlane RM. Dupuytren's contracture. In Green DP (editor): *Operative hand surgery*. New York, 1993, Churchill Livingstone.
26. Bruner JM. The zig-zag volar-digital incision for flexor tendon surgery. *Plast Reconstr Surg* 40:571, 1967.
27. Hueston JT. Dermatofasciectomy for Dupuytren's disease. *Bull Hosp Joint Dis* 44:224, 1984.
28. Hueston JT. The control of recurrent Dupuytren's contracture by skin replacement. *Br J Plast Surg* 11:152, 1969.
29. McCash CR. The open-palm technique in Dupuytren's contracture. *Br J Plast Sug* 17:271, 1964.
30. McFarlane RM, Botz JS. The results of treatment. In McFarlane RM, McGrouther DA, Flint MH (editors): *Dupuytren's disease: biology and treatment (hand and upper limb series)*. New York, 1990, Churchill Livingstone.
31. Jensen CM, Hangegaard M, Rasmussen SW. Amputations in the treatment of Dupuytren's disease. *J Hand Surg (Br)* 18:781, 1993.
32. Rabinovsky Ed, Weinfeld AB, Barrows T, et al. The role of transforming growth factor (TGF-6) in Dupuytren's contracture. *Am Assoc Hand Surg* (27th meeting abs) 54, 1997.
33. McFarlane RM. Dupuytren's disease. In McCarthy JG (editor): *Plastic surgery*. Philadelphia, 1990, WB Saunders.