



Workplace Safety and Insurance
Appeals Tribunal

Tribunal d'appel de la sécurité professionnelle
et de l'assurance contre les accidents du travail

Knee Conditions and Disability

Discussion paper prepared for

The Workplace Safety and Insurance Appeals Tribunal

August 2013

Prepared by:

Dr. John Cameron
M.D., F.R.C.S. (C)
Orthopaedic Surgeon

Contributing Editor:

Dr. Marvin Tile
C.M., M.D., B.Sc (Med), F.R.C.S. (C)
Professor Emeritus, Department of Surgery, University of Toronto
Orthopaedic Surgeon, Sunnybrook Health Science Centre

Dr. John C. Cameron graduated from the University of Toronto Orthopaedic Programme in 1978 and in 1979 travelled extensively visiting knee surgery centres in North America and Europe.

He joined the staff of the Toronto General Hospital in 1980 and transferred to the Holland Orthopaedic & Arthritic Centre of Sunnybrook Health Science Centre in 1991. He has been the surgical consultant for the University of Toronto Athletic Injuries Clinic for 33 years and the surgical consultant for the Mount Sinai Hospital, Athletic Injuries Clinic for 27 years.

Dr. Cameron has published many articles on knee surgery and his area of interest is complex knee ligament injuries and corrective osteotomies for mal-alignment about the knee.

Dr. Marvin Tile graduated from the University of Toronto Medical School in 1957. He did post-graduate training in Orthopaedic Surgery at the University of Toronto from 1958 to 1963, and was awarded the Royal College Fellowship in Surgery (Orthopaedics) in

1963. He was granted the Detweiler Fellowship in 1963 and travelled extensively in Europe, visiting leading orthopaedic centres. He joined the faculty at the University of Toronto in 1966 and holds the rank of Professor (Emeritus) in the Department of Surgery (Orthopaedics).

His clinical and research interests have been in orthopaedic trauma care, and also in the management of arthritis, including hip and knee arthroplasty. He also has a major interest in low back pain.

He has published widely, especially in orthopaedic trauma. He has authored two texts: *Fractures of Pelvis and Acetabulum*, Lippincott, Williams & Wilkins, 3rd Edition, 2003 and *Rationale of Operative Fracture Care* with Dr. Joseph Schatzker, Springer-Verlag, 3rd Edition, 2005, now in 6 languages. Since 1966, he has been on the Active Staff in orthopaedic surgery at Sunnybrook Health Sciences Centre, a University of Toronto, fully affiliated hospital. He was Chief of Orthopaedic Surgery at that institution from 1971 to 1985 and Chief Surgeon from 1985 to 1996. He has been elected to many prestigious positions. He was the founding president of the Ontario Orthopaedic Association (1978-1980), Past President of the International Society for the Study of Lumbar Spine (1986-1987), Past President of the Canadian Orthopaedic Association (1991-1992), and in 1992-1994, Past President of the AO Foundation, Switzerland (devoted to research and education in fracture care, world wide). As well, he was Chair of the Sunnybrook Foundation (1996-2001). An endowed Chair in Orthopaedic surgery has been established in his name at Sunnybrook HSC and the University of Toronto. Dr. Marvin Tile has been a medical counselor in orthopaedics for the Tribunal since 2004. He is a Member of the Order of Canada.

This medical discussion paper will be useful to those seeking general information about the medical issue involved. It is intended to provide a broad and general overview of a medical topic that is frequently considered in Tribunal appeals.

Each medical discussion paper is written by a recognized expert in the field, who has been recommended by the Tribunal's medical counsellors. Each author is asked to present a balanced view of the current medical knowledge on the topic. Discussion papers are not peer reviewed. They are written to be understood by lay individuals.

Discussion papers do not necessarily represent the views of the Tribunal. A vice-chair or panel may consider and rely on the medical information provided in the discussion paper, but the Tribunal is not bound by an opinion expressed in a discussion paper in any particular case. Every Tribunal decision must be based on the facts of the particular appeal. Tribunal adjudicators recognize that it is always open to the parties to an appeal to rely on or to distinguish a medical discussion paper, and to challenge it with alternative evidence: see *Kamara v. Ontario (Workplace Safety and Insurance Appeals Tribunal)* [2009] O.J. No. 2080 (Ont Div Court).

KNEE CONDITIONS & DISABILITY

Anatomy

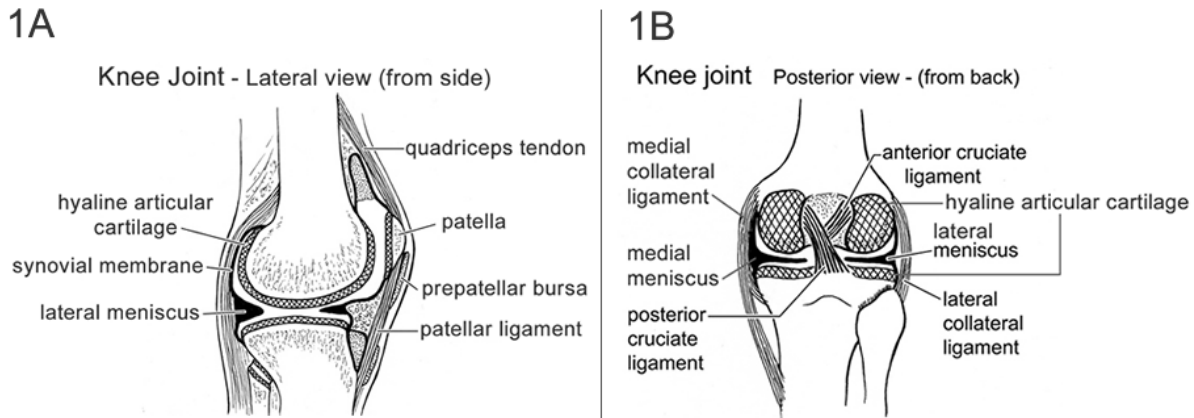


Figure 1 - Knee Joint: Gross Anatomical Appearance

1A, 1B - Normal appearance of the knee joint from the side (lateral, A) and from the back (posterior, B) view. Note the smooth articular cartilage surface, the menisci, and the synovial membrane. The ligaments give stability to this joint, the medial and lateral ligaments give side to side stability and the cruxiates front to back (anteroposterior).

1. *The knee is a synovial joint.* The synovial lining of the knee joint produces fluid in small amounts but excessive amounts of fluid in pathological conditions. The amount of fluid may increase with inflammation or injury (i.e. a meniscal tear or arthritis).
2. *Articular cartilage* is the smooth substance covering the end of the knee joint. It acts as a shock absorber and is seen as a space between the femur and tibia on an x-ray. Thinning of the cartilage space on a standing x-ray indicates arthritis. Articular cartilage can be damaged either by trauma or inflammatory conditions such as a rheumatoid or crystal arthritis.

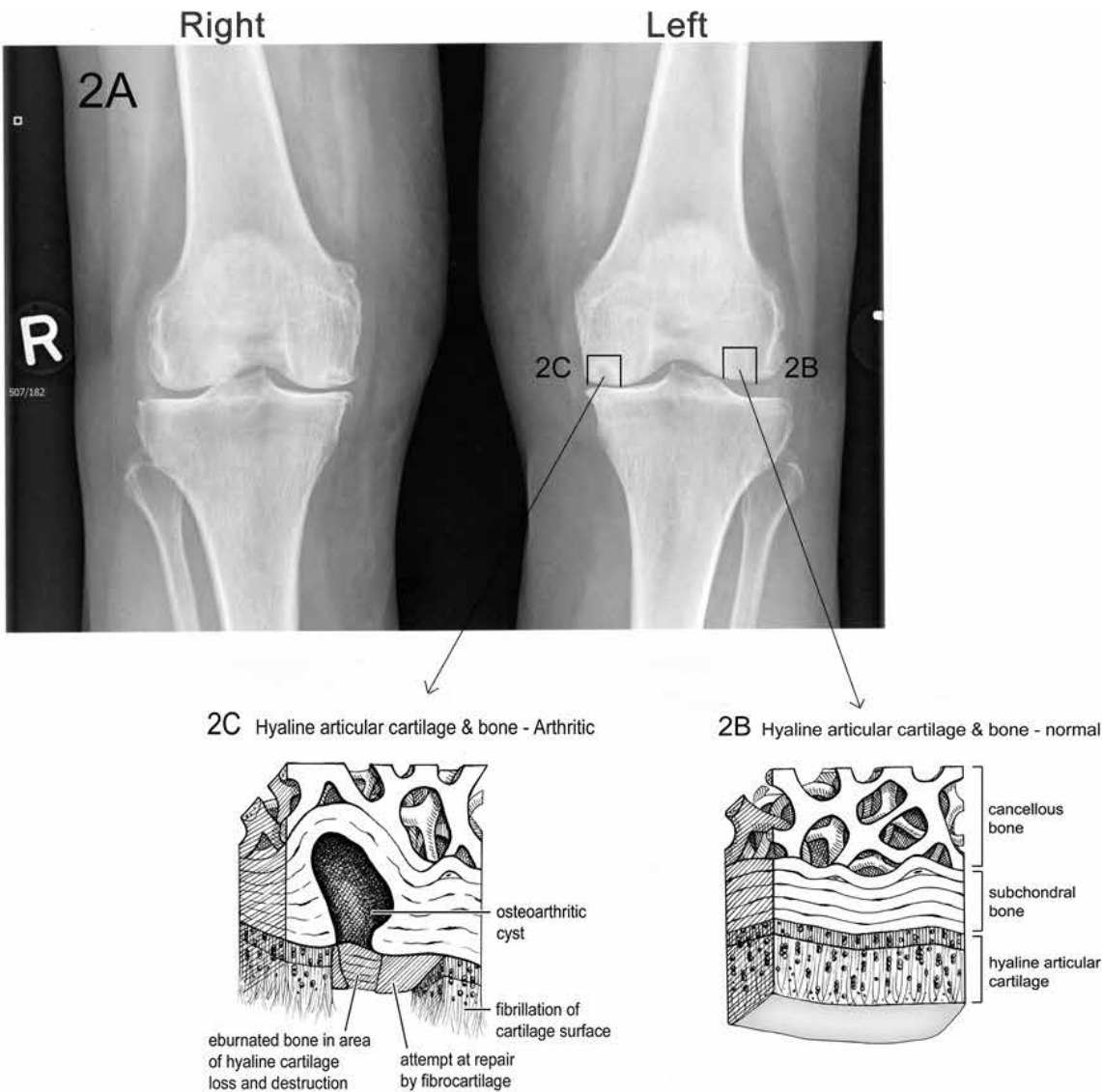


Figure 2 - Articular Cartilage Knee Joint

2A - Standing AP Image , Both Knees: The left knee has medial joint space narrowing indicating loss of articular cartilage and advanced Osteoarthritis of the medial compartment of the knee. The right knee has mild joint narrowing indicating mild medial osteoarthritis.

2B - Normal appearance of the articular cartilage: Normal Articular Cartilage of the Knee in cross section. The femoral condyle is covered by this very smooth surface; the microscopic section shows the layers of normal articular (hyaline) cartilage. Note the smooth surface; the cells on this surface have no blood supply, are nourished by diffusion of synovial fluid, and cannot regenerate, once damaged.

2C - Abnormal appearance of articular cartilage: Abnormal Osteoarthritic Joint surface of the knee in cross section. The surface is rough, with many defects on the surface. The microscopic section shows the ulcer, the attempt at healing with fibrocartilage. Eventually, the surface is covered with eburnated bone, a poor bearing surface.

3. The *meniscus* is a fibrocartilagenous, washer like structure, attached to the joint capsule. It increases the contact area between the convex surface of the femur and a flat tibial surface. It is an important load bearing structure within the knee joint. It has a very limited blood supply and, therefore, limited ability to heal if torn. The knee has two menisci, a medial on the inner part of the knee, and a lateral, on the outside part of the knee. Symptoms of a meniscus tear depend on the type and size of the tear, the location and the activity level of the patient. Loss of a portion of the meniscus can result in arthritis over a period of time.
4. *Ligaments*: There are four major ligaments in the knee joint. The collateral ligaments on the medial and lateral aspect of the knee provide side to side stability. The cruciate ligaments, in the centre of the knee, provide antero-posterior or front to back stability. Depending on the severity of the ligamentous injury and which ligament is torn, a person may complain of instability. An accurate diagnosis of which ligaments are injured is essential. (See Fig. 1A, 1B)
5. *Tendons* as knee stabilizers: The pes anserinus is made up of the insertion of the hamstring tendons on the anteromedial portion of the upper tibia and act as rigging wires to hold the mast up on a sailboat. This gives some medial and posterior stability to the knee. The popliteus muscle is in the posterolateral part of the knee and its tendon acts as a posterolateral stabilizer of the knee.
6. The *muscles* that cross the knee joint add to stability. People with muscle atrophy often complain of instability on the basis of poor muscular support for the knee. Circumferential measurement of the thigh can compare the injured to the normal leg. Strong muscles can often compensate for deficient ligaments. The quadriceps muscle group can compensate for posterior cruciate deficiency and the hamstrings can compensate for anterior cruciate deficiency. People with patello-femoral pain from osteoarthritis or mal-tracking, are unable to use their quadriceps effectively and often report a feeling of instability. Those people generally do not fall down, unlike the anterior cruciate deficient patient.

Physiology of the knee

The knee is a very complex joint. The usual range of motion is 0 to 145°. Limitation of range of motion can occur from injury, arthritis or physical limitations from obesity. The knee joint also rotates as it moves through its range of motion and it also “glides” or moves in an anterior posterior direction. It is required to move in all these directions and yet maintain stability. Lack of extension can occur slowly with arthritis or acutely with a meniscal tear or loose body. Lack of flexion can occur with swelling from any cause.

A mechanical block to extension, such as a meniscal tear may result in a fixed flexion deformity (lack of full extension) (see Fig. 7C). Osteoarthritis, swelling, pain from an injury or morbid obesity may limit full flexion.

How is a diagnosis of knee injury made?

A. History

What is the mechanism of injury?

The mechanism of injury will often be useful in determining the severity of the injury and the possible structures damaged. If a person has his foot planted and his knee is hit from the lateral side, then the commonest injury is an injury to the medial ligament but more severe injuries will include both anterior and posterior cruciate ligaments. The most severe will also involve injuries to the blood vessels at the back of the knee and potentially some of the nerves around the knee.

Location of pain

The location of the pain, both at the time of the injury and subsequent to the injury, will help to localize the site of the injury.

History of recurrence

It is important to document a history of prior similar injury. A person may have had a previous injury with a long history of recurrent instability with another episode of instability at work.

Onset of swelling

The onset of swelling is often important. Immediate swelling is generally bleeding within the knee secondary either to a fracture, dislocation of the patella, or major ligamentous injury. A slow onset of swelling is more indicative of an injury superimposed on arthritis or a meniscal tear, with increased production of synovial fluid.

Instability

Many people complain of instability. It is important to determine whether the instability is secondary to a ligamentous injury, patella instability, or poor function of muscles around the knee due to pain.

Spontaneous onset of knee pain

Knee pain may occur spontaneously without trauma. This is usually caused by inflammation, such as gout, pseudogout, rheumatoid or seronegative arthritis.

In people over the age of 30 – 35, a meniscal tear can occur with very little injury. Acute tendonitis can also occur without significant injury (enthesopathy). A minor twist

on an arthritic knee that was previously asymptomatic may result in the sudden onset of pain.

More serious problems, such as spontaneous osteonecrosis of the knee (SONK), are relatively rare.

B. Physical examination

Physical examination of the knee is very important. Often the physical examination is not well documented in the files of injured persons.

Point tenderness to palpation of the knee joint will often lead the doctor the area of the knee involved, be it anterior tenderness of the patella, or joint line tenderness indication meniscal pathology.

Alignment is extremely important. Whether or not the person is bow-legged (varus) or knock-kneed (valgus) will often determine how they recover from either ligamentous injuries or injuries superimposed on arthritis.

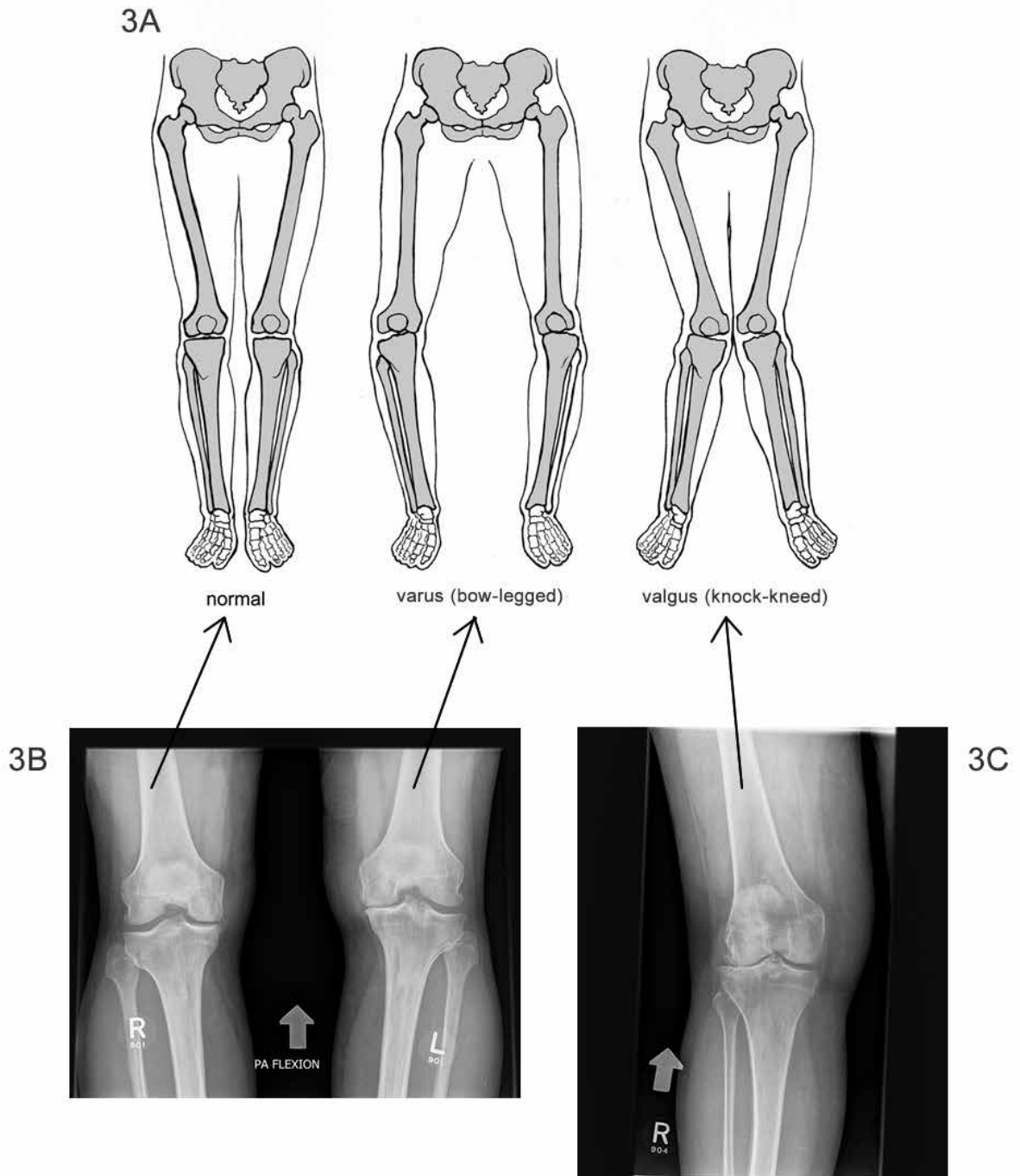


Figure 3

3A - Drawing depicting a normal knee alignment, varus (bowed legs) and valgus (knock knee) alignment

3B - A standing AP view of both knees showing normal alignment on the right and varus on the left

3C - Severe arthritis in the lateral compartment causing valgus deformation of the knee

Swelling of the knee should be documented and muscle atrophy with accurate measurement of thigh circumference at fixed points above the patella to measure muscle atrophy of the thigh. Ligamentous examination of the knee, both in the acute injury and subsequently is extremely important.

Range of motion examination of the knee, with respect to limitation of range of motion due to stiffness following injury is very important.

Crepitus or grinding in one or more of the three compartments of the knee on physical examination may be important. It is important for the examiner to determine whether the crepitus is from the soft tissues or from bone on bone grinding, indicating cartilage loss and osteoarthritis.

C. Investigations

(1) X-rays

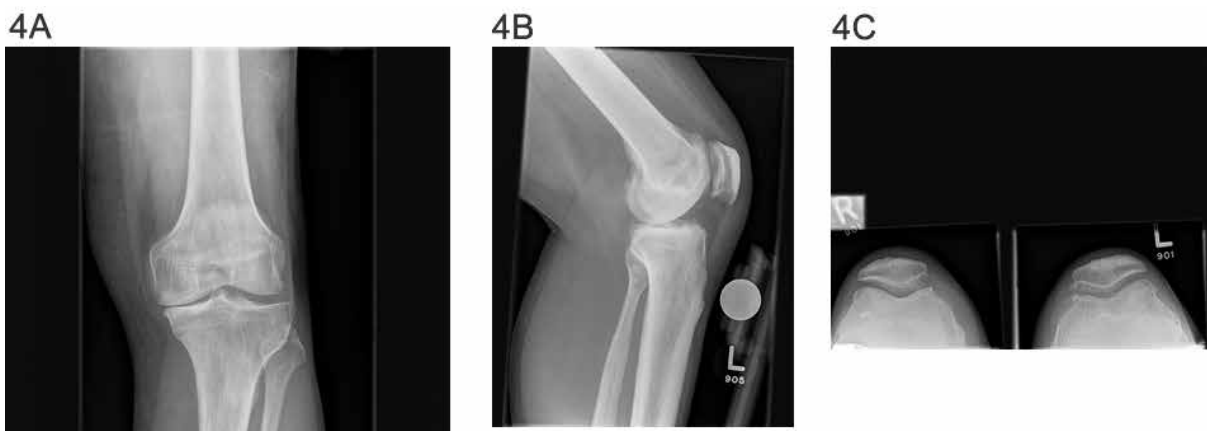

Figure 4 A,B,C - X-rays: Anteroposterior (standing), Lateral and axial patellar view of a primary osteoarthritic knee with varus deformity

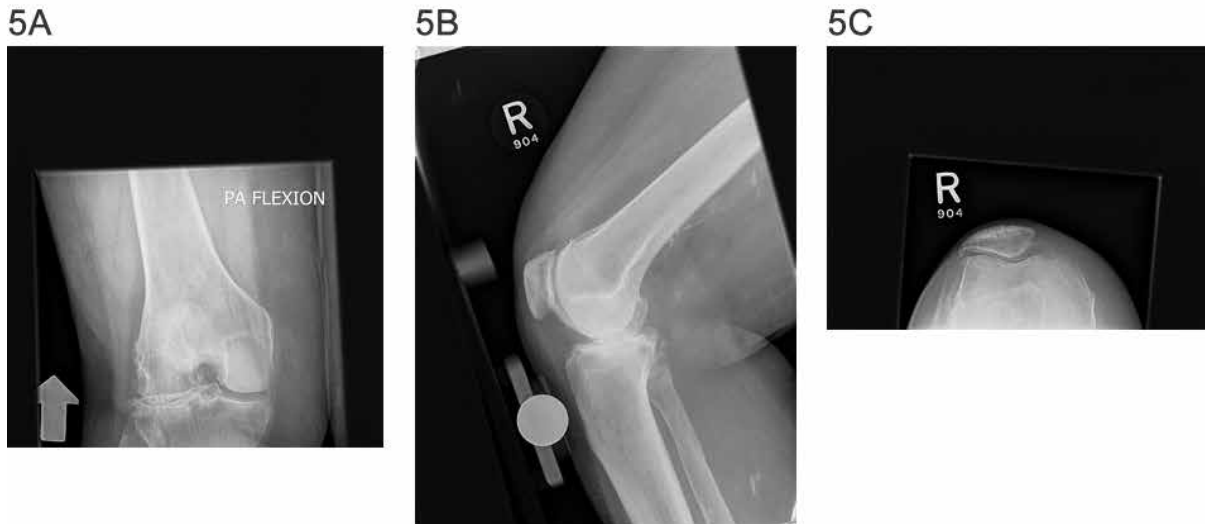

Figure 5 A,B,C - X-rays: AP (standing), Lateral and axial patellar view of a primary osteoarthritic knee with valgus deformity

X-rays are taken to determine if the patient has a fracture, abnormal anatomy, or arthritis. In order to make a diagnosis of arthritis, x-rays should be taken with the person standing and with the knee slightly flexed, in order to document any loss in height of the joint space. Documentation should be made of the patella or knee cap position and alignment and secondary changes such as osteophytes or spurs around the knee joint and bone abnormalities that affect the joint surface.

(2) MRI examination (see Fig.8,12)

MRI gives information regarding the soft tissues, such as ligament injury and meniscal tears.

(3) Bone scan

A bone scan will give information with regard to inflammation with increased uptake around the knee joint in inflammatory conditions, it will also be useful for diagnosing avascular necrosis which is a condition in which areas of the bone will die and produce pain, though in the early phase the x-rays are often normal.

(4) CT

Computerized tomography will give detailed information regarding bone abnormalities.

(5) Ultrasound

Ultrasound is not a very useful investigation for the knee. It is used primarily to diagnose tears of the quadriceps or patella tendons but MRI is a better examination if the diagnosis cannot be made clinically.

(6) Arthrogram

Arthrogram of the knee is seldom performed now. The current state of the art for investigating meniscal tear is the MRI.

(7) Role of the laboratory in arthritis

The use of ESR (erythrocyte sedimentation rate) and CRP (C - reactive protein) is primarily to rule out inflammatory causes of arthritis. Other tests include rheumatoid factor, HLA-B27 for ankylosing spondylitis, as well as aspiration of joint fluid for the presence of crystals (uric acid for gout and calcium pyrophosphate for pseudo-gout).

Specific conditions of the knee

A. Injury

(1) Fracture

Intra-articular fractures can cause damage to the articular cartilage of the joint surface resulting in deformity of the joint. Articular Cartilage cannot regenerate other than by a rudimentary fibrocartilage, therefore, these intra-articular fractures especially in a weight bearing joint such as the knee, may lead to progressive post traumatic arthritis.

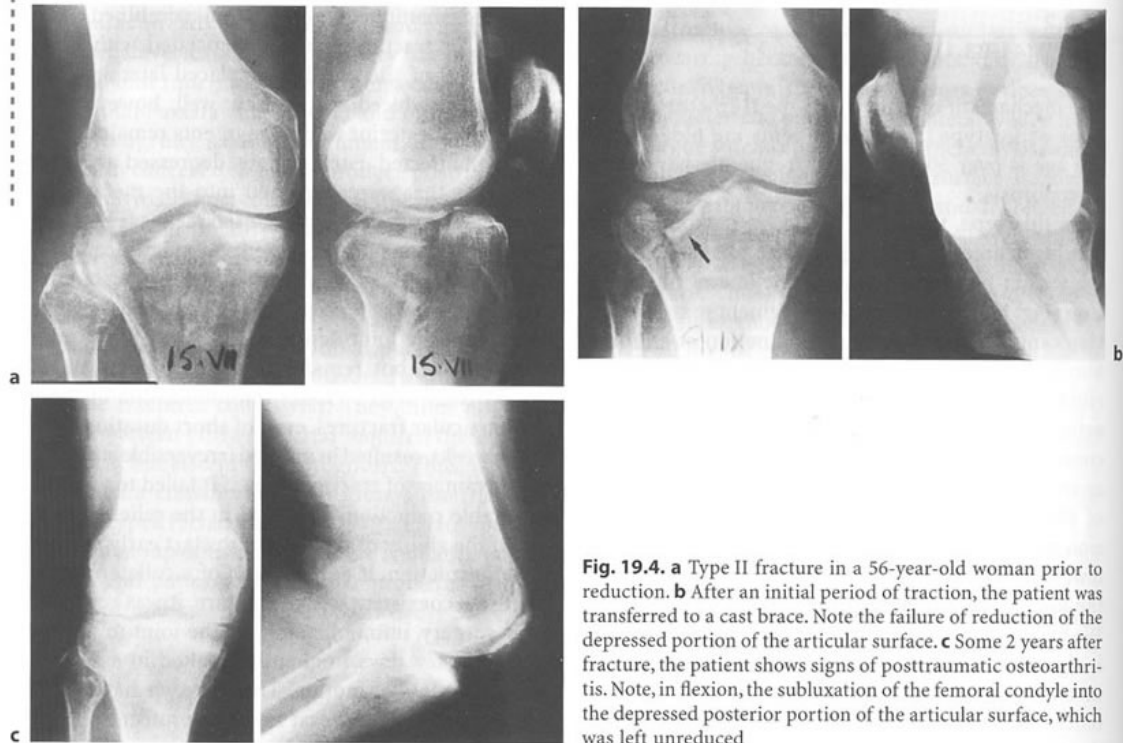


Fig. 19.4. **a** Type II fracture in a 56-year-old woman prior to reduction. **b** After an initial period of traction, the patient was transferred to a cast brace. Note the failure of reduction of the depressed portion of the articular surface. **c** Some 2 years after fracture, the patient shows signs of posttraumatic osteoarthritis. Note, in flexion, the subluxation of the femoral condyle into the depressed posterior portion of the articular surface, which was left unreduced

Figure 6 - Secondary Osteoarthritis due to malunion following a tibial plateau fracture, from *Rationale of Operative Fracture Care*, 3rd Edition, 2005, Schatzker and Tile, Springer-Verlag, Pg 450

Fractures can produce deformity and they can produce instability by associated loss of ligament stability.

(2) Ligament injury

Acute ligament injuries to the knee are caused by direct forces acting across the joint, or by indirect rotational forces. The injuries may involve a single ligament or multiple ligaments in more complex trauma.

The ligament injury may be a strain, that is, the fibres stretch in situ without rupture or the injury may be a complete tear or rupture in a single or multiple ligaments.

Whereas ligament strain rarely results in knee instability, complex tears involving more than one ligament often result in instability.

These injuries, especially ACL (Anterior Cruciate Ligament) tears, may also involve acute meniscal tears and injuries to the articular cartilage (loose bodies or articular impaction) and can be diagnosed with MRI. Surgical repair either acutely or secondarily may be necessary to prevent instability.

Recurrent episodes of instability can lead to osteoarthritis.

Ligament injury can also result in stiffness which is associated with pain and can also result in deformity, which can result in abnormal loading and premature arthritis.

(3) Meniscus tears

There are two general types of meniscal tears; acute tears, which usually occur in younger people after trauma, and degenerative tears, which typically occur in older people with minimal or no trauma.

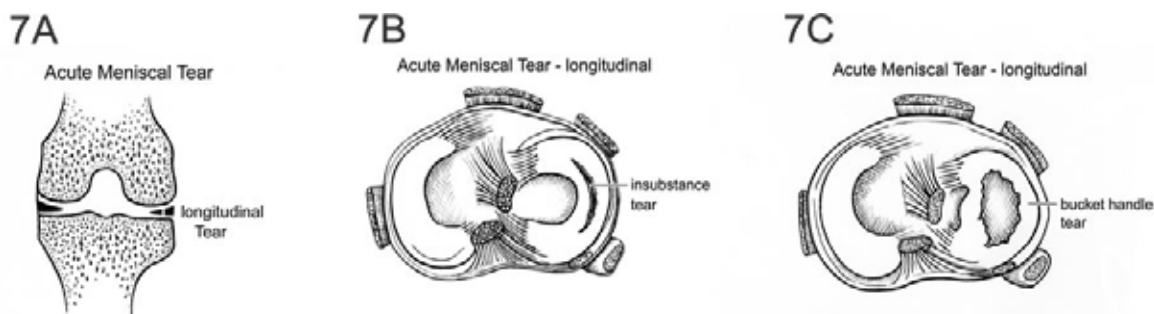


Figure 7 - Acute Meniscal Tears

7A - Acute insubstance longitudinal tear as seen in cross section (MRI View)

7B - The same tear seen from above in the joint (OR or arthroscopic view).

7C - Bucket handle tear: if the tear is complete, the medial portion may displace into the center of the joint, causing locking

Acute meniscal tears (see Fig. 7A, 7B, 7C) in young people may be isolated or associated with complex ligament injuries. These tears are usually longitudinal and insubstance. If symptomatic and at the periphery, these tears may be amenable to repair (see Fig. 10A, 10B). These tears as noted on MRI and at arthroscopic surgery usually have longitudinal or radial patterns. A fully displaced tear may displace into the centre of the joint, such as a bucket handle, and may cause the joint to lock (inability to straighten, see Fig. 7C). Radial tears may continue to evolve and progress to become a parrot beak tear (see Fig. 8A, 8B).

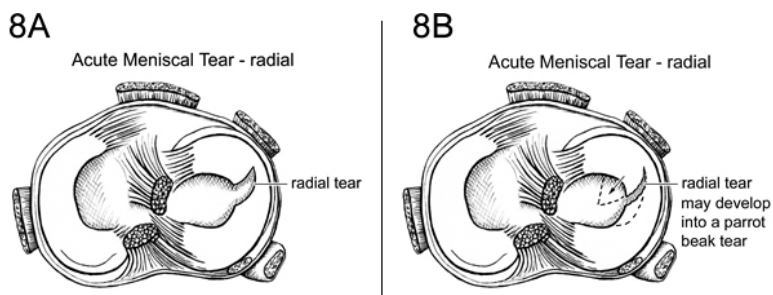


Figure 8 - Acute Radial Tears

8A - Acute radial tear may extend and become a full parrot beak tear - 8B

Degenerative tears, (see Fig. 9A, 9B, 9C, 9D) usually in older people, are often associated with osteoarthritis. It is often difficult to determine whether the symptoms are due to the meniscal tear or the associated arthritis. These tears are usually horizontal, flap or complex types. They are found on a high percentage (up to 90%) of MRIs in people with known osteoarthritis of the knee. There is no relationship to a history of trauma. As in all meniscal tears, they may cause symptoms of pain, locking, giving way and/or swelling or they may be asymptomatic. It is often difficult to distinguish the symptoms associated with the Osteoarthritic knee from those of the degenerative meniscus.

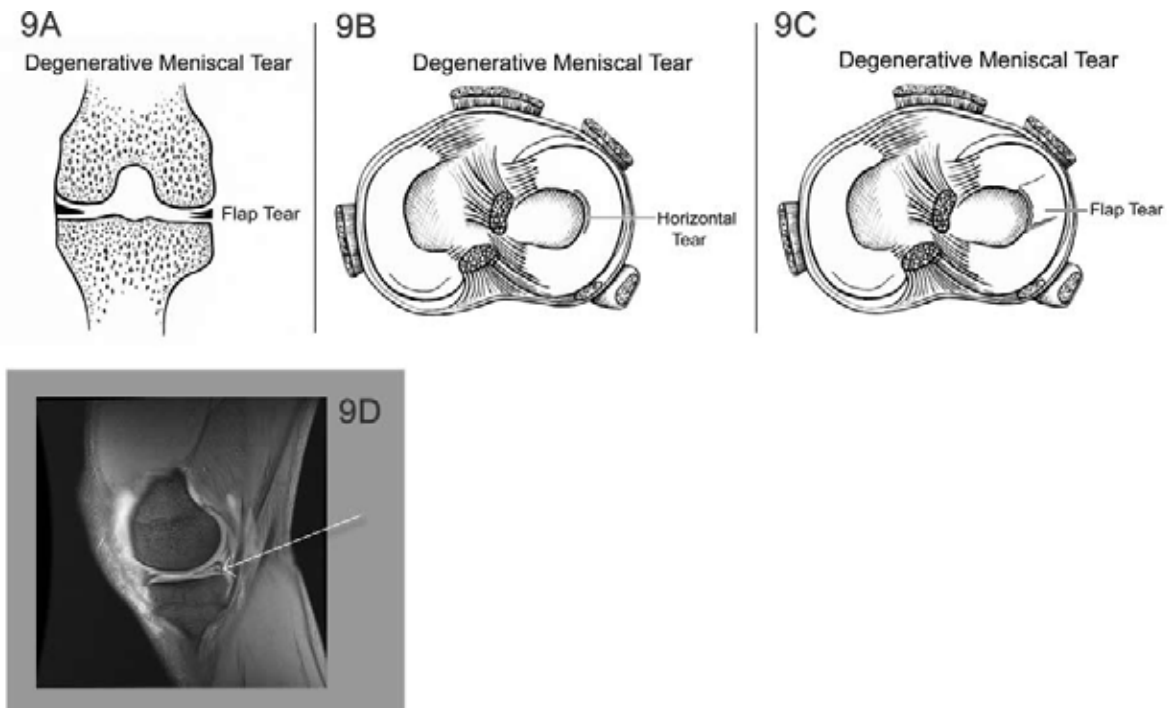


Figure 9 - Degenerative Horizontal Tears

9A - Horizontal, usually degenerative tear seen on cross section (MRI view)

9B - the same tear seen from the top within the joint (arthroscopic view)

9C - The tear may progress to a flap type

9D - MRI showing a horizontal tear (arrow)

Consequences of a meniscal tear:

Acute traumatic tears: (see Fig. 7,8,10)

These tears usually occur in the younger age group and are most likely longitudinal or radial. The trauma may be a minor twist on the flexed knee in the weight bearing position or part of a complex ligament injury to the knee, usually an ACL rupture.

Meniscal tears rarely heal, unless the tears are in the outer rim where there is a blood supply. Even if they do not heal, the knee may become asymptomatic with non

operative treatment. If symptoms persist or recur, surgery is indicated. Arthroscopic knee surgery is the commonest orthopaedic intervention worldwide.

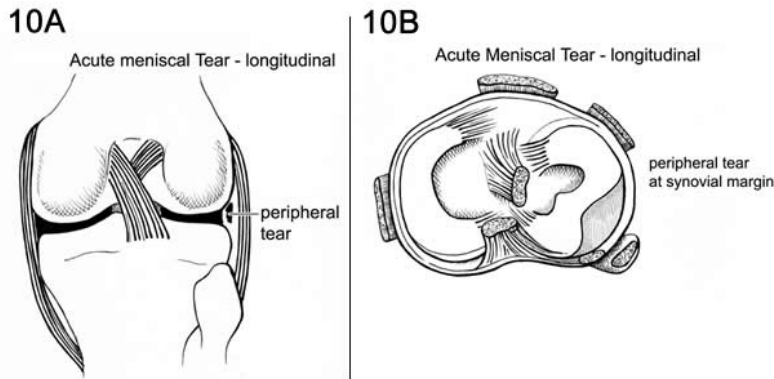


Figure 10

10A, 10B - Drawings showing a peripheral meniscal tear, really a separation from the synovial attachment. Since they are separated from the synovium, they have some blood supply. If reattached surgically, they have a high rate of healing, thereby preserving the meniscus and its important function.

The surgical procedures include partial meniscal resection, or meniscal repair if amenable. These are usually longitudinal tears in otherwise normal knees.

If the ACL is ruptured, it is usually repaired at the same time to restore knee stability and prevent further injury to the repaired meniscus.

In the short term, the results of these interventions are good; symptoms of pain, swelling, locking and giving way are usually alleviated.

In the long term, studies have shown an increasing percentage of knees with acute meniscal tears, especially those requiring early surgery and/or ACL repair will develop radiographic signs and symptoms of knee osteoarthritis.

Degenerative tears: (see Fig. 9)

As noted above, degenerative tears are found in a high percentage of knees with osteoarthritis. In the 50-60 year age group, the incidence is greater than 50%. They may be considered as age related changes that are seen in other joints and in the spine.

This makes it difficult for the clinician to determine whether the symptoms are due to the underlying osteoarthritis or the degenerative tear, usually horizontal, or flap type. Most people are treated for the primary osteoarthritis, but surgery may be indicated if symptoms of internal knee derangement persist. These symptoms are swelling, locking and giving way, associated with pain.

The intervention may be partial meniscectomy with debridement, and should only be done for these strict indications. Osteoarthritis is already present; therefore the ultimate prognosis is guarded. Some people with deformity may be made worse after meniscal surgical intervention.

Relationship of meniscal tear to osteoarthritic knee: cause and/or effect?

This may be a very difficult question to answer. Each case must be examined on its own merits. The guidelines have been outlined above, for both the acute traumatic tears, and the chronic degenerative tears associated with osteoarthritis. Acute traumatic tears in time may lead to radiographic and subsequent clinical osteoarthritis. This is more prevalent in complex ligament trauma, such as ACL tear, associated with meniscal tear. In the people with chronic degenerative tears, osteoarthritis is already present. In these people, the symptoms may be more related to the osteoarthritis than the tear. However, in some, symptoms of internal derangement may develop requiring intervention. In this group, the outcomes may be unpredictable.

Therefore this continues to be a controversial subject. There is controversy over whether or not arthroscopy plays a role in the management of osteoarthritis with associated meniscal tears. It often takes an experienced surgeon to determine whether or not the person with a combination of meniscal tear and osteoarthritis, would benefit from arthroscopy.

(4) Quadriceps Muscle tear from Patella

Tears of the quadriceps muscle and tendon from their insertion into the upper pole of the patella are not uncommon. These tears almost always occur through areas of degenerative tendinitis. They are more prevalent in older males, and more frequent in people with gout or pseudogout. The degenerative tendon may tear with minor trauma, usually a fall with sudden contraction of the quadriceps tendon. The diagnosis is made clinically and confirmed with ultrasound or MRI. X-rays will rule out a patellar fracture. The tears may be complete or incomplete, the complete tears requiring operative care to restore the extensor mechanism to the knee.

The clinical picture includes point tenderness at the upper pole of the patella, swelling and bruising, and an inability to actively extend the knee.

The so called patellar lag test is diagnostic. If the person with this injury is asked to actively extend the knee, they usually lack the last 20 degrees of extension. From that point, the examiner can passively further extend the knee to its normal straight or 5 degree hyperextended position. The difference between the active extension of -20 and the passive full extension is the patellar lag. Ultrasound and/or MRI will verify the tear.

If the diagnosis is made early and surgical repair done, the prognosis is excellent. Unfortunately, some are missed, leaving the person with a weak extensor mechanism, and a tendency for the knee to give way, especially on stairs.

Tears may occur in the patellar tendon distally from the patellar or tibial insertion, but are much more uncommon.

B. Osteoarthritis of the knee (see Discussion Paper : Osteoarthritis, WSIAT, Tile, 2008)

(1) Primary osteoarthritis

There is no known cause. The incidence is age related, increasing with age. There are some definite familial or genetic factors involved and most are bilateral. It is commoner in females, and in people with high BMI (obesity).

(2) Secondary osteoarthritis

There are many causes of secondary arthritis including:

- Injury, bony, fracture (Soft tissue; ligament, meniscus)
- Infection
- Other inflammatory arthritis, eg gout, pseudogout, Lupus
- Rheumatoid arthritis
- Seronegative arthropathies, e.g. Ankylosing spondylitis, Reiter's disease,
- Associated with inflammatory bowel disease, Psoriatic arthropathy

(3) Osteoarthritis Grading (see Fig. 2,4,5)

Osteoarthritis can be graded using x-ray criteria. These x-rays must be standing or weight bearing x-rays and are best taken with the knee flexed approximately 15 degrees to best illustrate joint space narrowing.

Early signs show osteophytes or spurs at the margin of the joint and late stages show complete loss of joint space in one or more of the three compartments (medial/lateral/patello-femoral).

(4) Arthroscopic grading of osteoarthritis is also useful

- Grade i is softening of the articular cartilage.
- Grade ii shows splitting and fibrillation.

- Grade iii shows major fibrillation and bone can be felt through the cartilage with the use of a probe.
- Grade iv is complete loss of articular cartilage, with exposed bone.

(5) Natural history of osteoarthritis

A) Primary osteoarthritis (see Fig 4,5)

This tends to occur in older people with a slow progression of symptoms. There is a familial trend and many cases are bilateral. Other joints e.g., large joints such as the hip, and small joints, such as the MP and IP joints of the hands and feet are often affected.

The symptoms may increase with a superimposed injury, (i.e. a meniscal tear with pre-existing osteoarthritis). In these cases the injury did not cause the osteoarthritis but the symptoms were precipitated by the injury and may be persistent because of the underlying osteoarthritis. With time and medical care, the symptoms often return to the pre injury clinical state.

B) Secondary osteoarthritis (see Fig.6)

Some of the common causes of secondary osteoarthritis are listed above. In general, the natural history is related to the cause. With respect to injury, this is usually related to a prior joint fracture or ligament injury. The intra-articular fracture damages the joint directly. It may also produce a deformity which alters the knee mechanics, causing further joint damage. Deformity such as varus or valgus places increased stress on the affected knee compartment and may lead to more rapid articular cartilage damage and a worse prognosis.

Ligament injuries can result in recurrent instability but many can be treated conservatively. Isolated medial ligament injuries are generally treated conservatively and many other ligamentous injuries in older people will be treated conservatively with physiotherapy and/or bracing. As people get older, the complications following ligamentous repair are often greater than the instability. Recurrent instability due to ACL injury can result in secondary osteoarthritis.

The consequences of meniscal tears have been discussed previously. Acute meniscal tears treated nonoperatively or operatively, usually, in time, will result in radiographic and/or clinical osteoarthritis. Chronic degenerative tears are part of the picture of the osteoarthritic knee.

C) Dislocation of the patella

Acute patella dislocations result in a large amount of swelling and thigh muscle atrophy. If bleeding occurs into the knee acutely, an intra-articular fracture from the

patella or femoral condyle must be suspected. Many people will continue to have patello-femoral or knee cap pain on the basis of muscle atrophy of their thigh with resulting mal-tracking of their patella.

If underlying abnormal anatomy, such as patella alta (which is a high riding patella) or a valgus knee (which is knock-kneed alignment) or external tibial torsion (with the foot pointing out or laterally with the knee pointing forward) exists, this will make rehabilitation very difficult following injury to the patella.

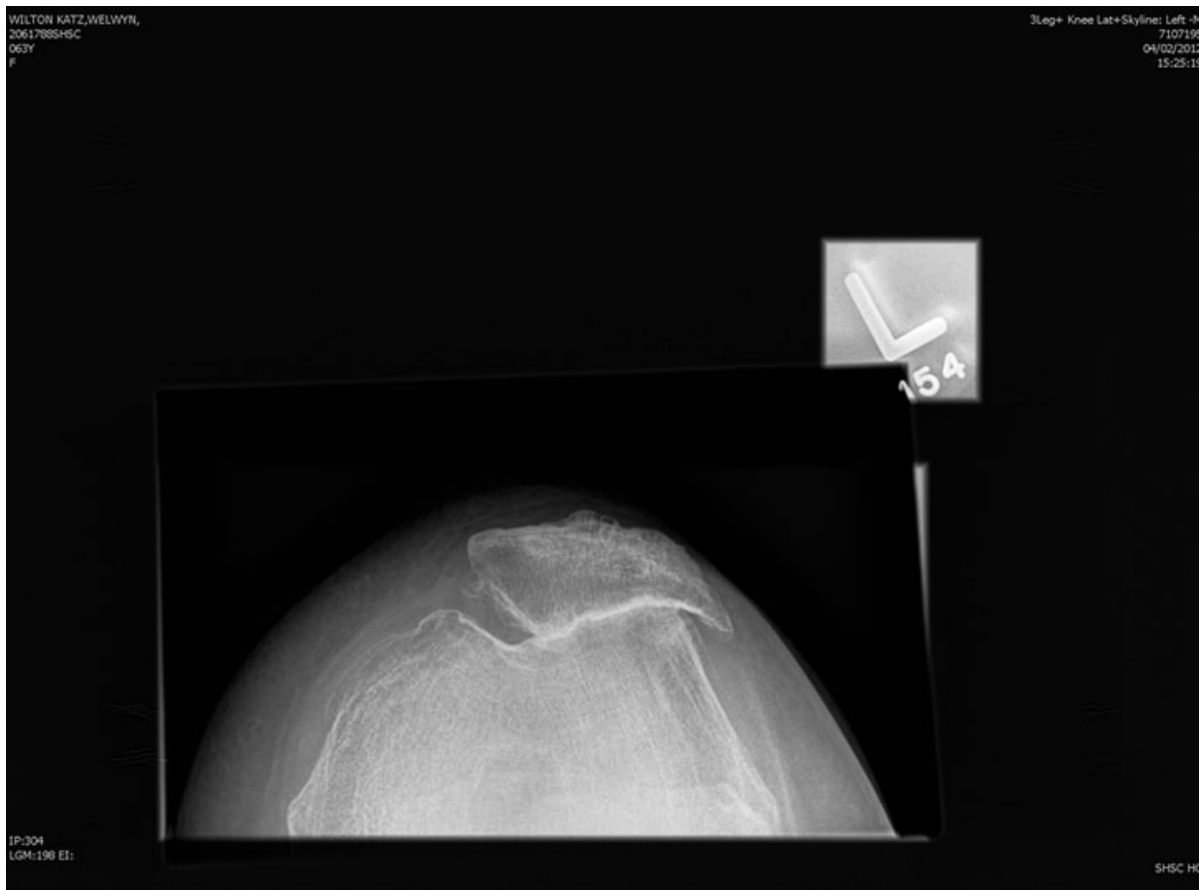


Figure 11 - An axial or skyline view of the patella on x-ray showing severe patellofemoral arthritis and lateral displacement of the patella. Note the complete lack of articular cartilage along the lateral patellar facet articulating with the underlying femoral condyle.

D) Baker's cyst

Baker's cysts are very common and are noted in a high percentage of ultrasounds. The use of ultrasound for knee diagnosis is not very useful. True Baker's (or popliteal) cyst occurs as a result of some intra-articular pathology i.e. like a meniscal tear, osteoarthritis or inflammatory arthritis such as rheumatoid. The cyst generally settles once the underlying pathology is dealt with. There is usually no indication to deal directly with the cyst.

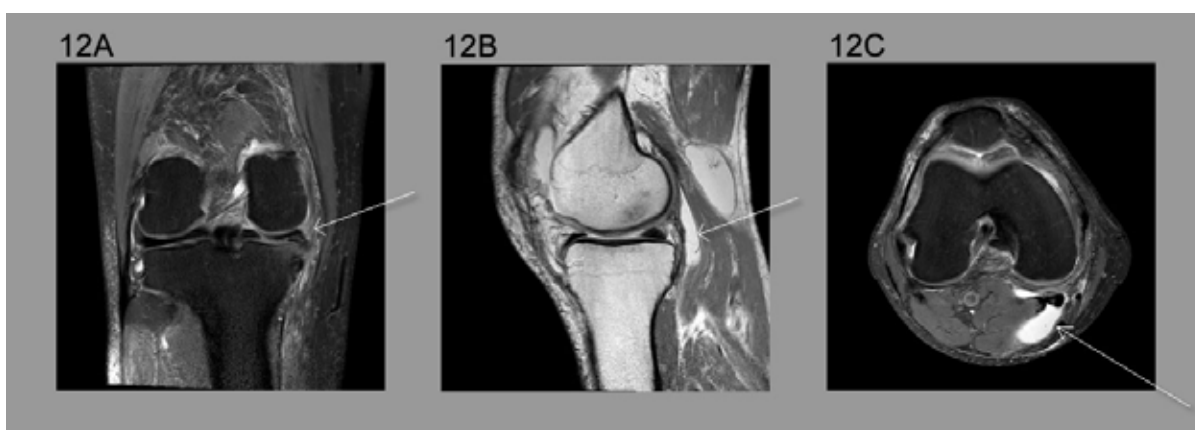


Figure 12 - Baker's (Popliteal) Cyst, MRI views

12A - Anteroposterior MRI, note the horizontal tear in the medial meniscus (arrow). In adults, Baker's cysts arising from the knee are often associated with a meniscal tear as in this case.

12B - On the lateral view, the cyst (seen by arrow) is noted posterior to the joint in the popliteal fossa.

12C - Axial MRI view showing the Baker's cyst behind the knee (arrow).

Difficult problems to resolve

A. Pre-existing arthritis

The injured person may have pre-existing arthritis of the knee, and because it develops slowly, they are not aware of it until an injury is superimposed on it. The resulting disability is often greater than one would expect for the amount of trauma. These people will often lose significant muscle strength which affects their knee stability and ability to recover. A particularly difficult problem is the person who has mild symptoms of osteoarthritis and then suffers a meniscal tear. Many of these people do poorly with arthroscopy due to the relative significance of the arthritis. The decision to consider arthroscopic surgery may be difficult. If the surgery results in considerable swelling and muscle atrophy, the return to pre-injury status is often dependant on the resolution of swelling and the recovery of muscle strength.

B. Patella mal-tracking and injury

Many people will develop patello-femoral pain or anterior knee pain following an injury. This can be secondary to either atrophy of the quadriceps, or to an underlying anatomical abnormality such as patella alta (which is a high riding patella), a valgus knee (which is knock-kneed alignment), or external tibial torsion (which is external rotation of the foot relative to the knee). (See Fig. 3) Any situation like this that results in atrophy of the quadriceps, specifically vastus medialis, or the medial quadriceps, will result in mal-tracking of the patella and patello-femoral pain. This can even occur in people with no evidence of patello-femoral osteoarthritis. Fortunately, most of these

people respond to physiotherapy and when they regain their quadriceps function, their patello-femoral or anterior knee pain resolves. Unfortunately, there are some people with underlying anatomical abnormalities or patello-femoral arthritis, who do not respond to physiotherapy and continue to remain disabled. People with patello-femoral pain have great difficulty climbing, descending stairs and walking on uneven ground as well as lifting.

C. Prior ligamentous injury and re-injury

There are people who function reasonably well after an injury such as an anterior cruciate disruption. However, if they are in a situation that results in an episode of instability of their knee due to their chronic anterior cruciate deficiency, then there are some work site situations that are potentially dangerous. Anyone with a significant ligamentous instability is at risk with certain jobs such as climbing scaffolds.

Point tenderness to palpation of the knee joint will often lead the doctor to the area of the knee involved, be it anterior tenderness of the patella, or joint line tenderness indication meniscal pathology.

The Importance of an accurate diagnosis

It is often helpful for the person to know exactly what his injury is. If the person knows what the natural history of the injury is and how the various treatments will affect the outcomes, then the person can participate in the treatment. Accurate diagnosis helps the physiotherapist to help the person recover. An accurate diagnosis will also help with person placement with respect to the need for job modification on either a temporary or permanent basis.

There is very little evidence that repetitive loading of a normal knee produces pathology or injury. i.e. working over rough terrain.

Also, an altered gait produced by problems in one joint (i.e. Knee), is unlikely to cause symptoms in the opposite knee (see discussion paper, Symptoms in the Opposite or Uninjured Leg, WSIAT, Harrington, 2005).

It should be noted that pathology such as medial compartment arthritis in a varus (bowlegged) knee is often symmetrical and more related to the age of the individual, as well as the onset of general familial arthritis. (See discussion paper, Osteoarthritis, WSIAT, Tile, 2008).